

## Management of Metastatic Colorectal Carcinoma with GcMAF Forte and Thymus Peptides: A Case Report

Dmitry Klokol<sup>\*</sup> and Mikhail Teppone

Stellar Biomolecular Research, Germany

<sup>\*</sup>Corresponding author: Dmitry Klokol, Stellar Biomolecular Research, Germany, Tel: +60169687977; E-mail: dr.dmytro@sbi-europe.com

Received date: July 11, 2016; Accepted date: August 18, 2016; Published date: August 31, 2016

Copyright: © 2016 Klokol D, et al. This is an open-access article distributed under the terms of the Creative Commons Attribution License, which permits unrestricted use, distribution, and reproduction in any medium, provided the original author and source are credited.

### Abstract

In the recent years immunotherapy has gained important role in cancer management. Immunostimulating effects of thymus-derived peptides on carcinogenesis have been actively studied in both animals and humans. Gc protein derived macrophage-activating factor (GcMAF) was found to have potent effect on macrophage phagocytic activity. Immunostimulating effects of GcMAF and peptides of thymus can be effectively combined together and with other treatment modalities of cancer. The current case report demonstrates outcomes of combination of GcMAF Forte and HT Thymus (peptides of thymus) in the management of metastatic colorectal adenocarcinoma. This case study suggests that individually prescribed immunotherapy can be a promising alternative in management of advance forms of cancer, especially when options of treatment are limited.

**Keywords:** Colorectal cancer; GcMAF; Thymus peptides; Immunotherapy; Metastatic cancer

### Introduction

Liver is the most common site of metastasizing of colorectal cancer. Secondaries in liver are found in 25-35% of patients going for surgery of primary colorectal tumors [1]. Simultaneous removal of solitary metastatic liver nodules during the primary operation is widely performed by surgeons all around the world for the last 50 years and has become a golden standard. According to the National Cancer Institute's SEER database the 5-year survival rate for stage IV colorectal cancer is 11-12%. In case of recurrence of liver metastasis after the single-stage surgical removal of primary tumor and secondary liver nodule, patients with resectable disease have median survival 14-20 months, and patients with unresectable disease have median survival 4-12 months. In spite of existing chemotherapeutic regimens 5-year surviving rate is only 0-2% [2].

In recent years immunotherapy is gaining popularity in treatment of advanced form of cancer due to its minimal toxicity and outstanding safety compared to conventional chemotherapy. Researchers are studying effects of thymus-derived peptides on carcinogenesis of various forms of cancer. Thymus peptides have a very high potential to regulate its functional activity by stimulating the development and maturation of functional T-cells in the central medulla of thymus. The matured functional T-cells enter the circulation and provide adequate adaptive immune system response [3].

Apart from T-cells, macrophages also play a vital role in anticancer immunity. Macrophages provide phagocytosis of cancer cells, release TNF (tumor necrosis factor) and other cytokines that cause tumor cytolysis, induce apoptosis of tumor cells, reduce neoangiogenesis in the tumor site, and induce proliferation and activation of other immunocompetent cells. The research of Dr. Nobuto Yamamoto has discovered the role of Gc protein-derived macrophage-activating factor (GcMAF) in increasing phagocytic activity of macrophages, significant anticancer effects, and antineoangiogenesis effect [4].

So far we did not come across publications on application of GcMAF and thymus peptides in management of colorectal cancers. The case presented below appeared interesting to us as there is an insufficient data on efficacy of such approach to treatment of advanced forms of cancer.

### Case Report

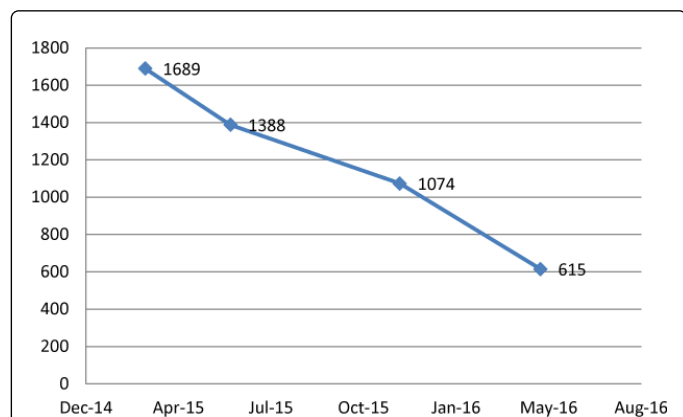
A 34-year old patient was diagnosed with sigmoid adenocarcinoma in June 2013. In August 2013 patient underwent sigmoid colectomy in one of the private medical centers during which a solitary subcentimeter liver nodule was noted and removed. Histopathological report of the surgical specimen concluded moderately differentiated adenocarcinoma (T3N1M1). Histopathology report confirmed that liver nodule was consistent with primary lesion. All margins were clear. Four out of the 15 regional lymph nodes were positive for adenocarcinoma. Post-operative period was uneventful and patient recovered well. Patient received first-line adjuvant chemotherapy with FOLFOX regime (Oxaliplatin plus 5-fluorouracil and leucovorin). Patient was under follow up by surgeon and oncologist. Six months after the completion of FOLFOX regime the serum CEA level start elevating. Repeated CT scan of thorax, abdomen and pelvis showed presence of secondary lesions in the right lobe of liver as well as aorto-caval lymphadenopathy. Otherwise no evidence of local recurrence, or chest lesions was found. Patient was not agreeable for any invasive treatment, i.e. ablation therapy, hepatic arterial infusions or surgical intervention, however, agreed for second line chemotherapy. FOLFIRI regime was given (Irinotecan plus folic acid, 5-fluorouracil, and leucovorin). Although patient experienced some side-effects of chemotherapy, such as diarrhea, fatigue and lowering of blood counts, six cycles of chemotherapy were completed. Restaging PET-scans after second line chemotherapy showed avid liver lesions. Patient refused for any further treatment and even defaulted follow up for the next 10 months. Subsequently, when returned for the follow up patient presented with pain in the right hypochondrial region with a palpable mass in that area, fatigue, loss of appetite, deranged liver function test due to increased levels of transaminases, gamma-glutamyltransferase

and alkaline phosphatase, and significantly elevated serum CEA level. CT scan demonstrated a huge lesion in the right lobe of liver up to 14 cm in the largest diameter and 4 smaller lesions 2-3 cm in diameter, also located in right lobe.

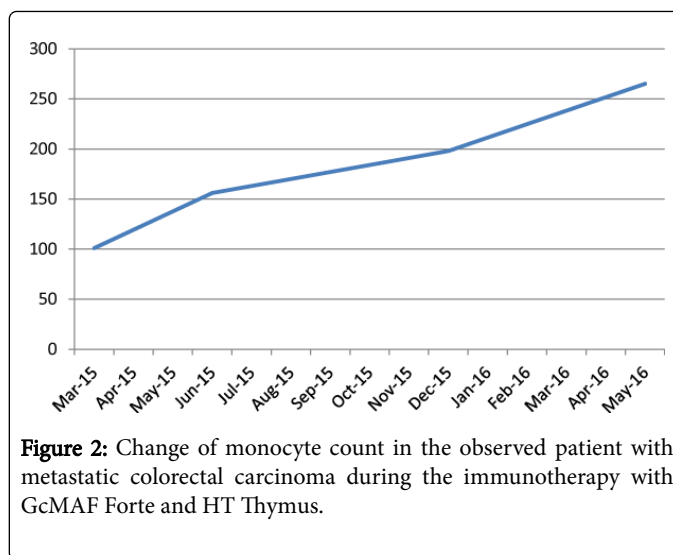
In March 2015 patient and family decided to opt for immunotherapy with GcMAF and peptides of thymus. Therapy consisted of GcMAF Forte (GcMAF combined with HNW-HA - high molecular weight hyaluronic acid; LabRMS Therapeutics Ltd) 2 ml subcutaneous injections weekly, and HT Thymus (thymus peptides extracts, MF Plus Ltd) 500 mg intramuscular injections 3 times per week. In addition, supplementation with vitamin D3 4,000 IU per day was given to enhance the effect of GcMAF. Duration of each treatment cycle was four months. As a complementary diagnostic tool, prior to commencement of immunotherapy radio-thermometry was done, findings of which corresponded to the findings of the CT scan: measurements showed increased internal temperature in the areas of liver lesions by 2-3 degrees.

Two months after the commencement of the immunotherapy with GcMAF Forte with HMW-HA (LabRMS Therapeutics Ltd) and HT Thymus (MF Plus Ltd) patient had a dramatic improvement of clinical symptoms, such as pain, fatigue and loss of appetite. After the completion of initial course of treatment with GcMAF Forte and HT Thymus liver function test has completely normalized, serum carcinoembryonic antigen (CEA) level reduced and radio-thermometry showed reduction of temperature in the areas of liver lesions.

Resting period between cycles of immunotherapy was 2 months. In September 2015 administration of GcMAF Forte and HT Thymus was continued. During the period of treatment there was a significant decrease of CEA level (Figure 1) and increase in monocyte count (Figure 2). Liver function test had a slow tendency towards normalization. Imaging study showed a stable disease, and radio-thermometry demonstrated normal internal temperature in the site of the liver lesions. There were no side-effects from the treatment with GcMAF Forte and HT Thymus.



**Figure 1:** Change of serum CEA levels in the observed patient with metastatic colorectal carcinoma during the immunotherapy with GcMAF Forte and HT Thymus.



**Figure 2:** Change of monocyte count in the observed patient with metastatic colorectal carcinoma during the immunotherapy with GcMAF Forte and HT Thymus.

## Discussion

Metastatic liver lesions are commonly encountered in colorectal cancers and contribute to increased mortality in this group of patients [1]. In spite of surgical resection in combination with chemotherapy being considered as a golden standard of treatment, such approach has its limitations. Firstly, less than 25% of lesions are resectable with 5-year survival rate maximum up to 35%, and secondly – not all patients are agreeable for surgery and/or chemotherapy due to high morbidity rate and numerous side-effects [2].

Such situation creates room for immunotherapy. Both GcMAF Forte and HT Thymus extracts have minimal side-effects and toxicity. GcMAF Forte allows achieving good control over tumor progression by direct activation of phagocytosis and stimulation of TNF- $\alpha$  release, hence inducing necrosis inside the tumor. A formulation of GcMAF Forte (LabRMS Therapeutics Ltd) with HMW-HA provides a slow release of the active ingredient and reduces the frequency of administration to one week.

The HT Thymus (MF Plus Ltd) is a mixture of purified, fractionated and filtrated peptides derived from the animal thymus. Peptides of the thymus regulate activity and induce differentiation of T-lymphocytes, thus may contribute to the host defense against cancer. Studies have reported that thymus extracts reduce the risk of infectious complications in patients undergoing cancer treatment and also might have beneficial effects on survival rate [3,5].

Previously both GcMAF and thymus peptides were independently administered as a complementary treatment to chemotherapy with the aim to enhance its efficacy and alleviate negative immunosuppressive effect of chemotherapeutic agents [6,7]. This case report suggests that combination of GcMAF Forte and HT Thymus is a safe, non-toxic method of cancer immunotherapy that can help to achieve better outcomes in patients who are not subjects for surgical resection and/or chemotherapy. We propose that further clinical and scientific research will gain more data on efficacy of GcMAF Forte and HT Thymus in cancer management and improve existing immunotherapy protocols.

## Disclosure

No funding was received during the preparation of this article. Stellar Biomolecular Research is a non-for-profit organization and has no commercial interest in this publication.

Patient and family expressed no objections to this publication, however did not agree to share imaging data.

## Conflict of Interests

Authors declare no conflict of interests regarding the publication of this article.

## References

1. Sheth KR, Clary BM (2005) Management of Hepatic Metastases from Colorectal Cancer. *Clin Colon Rectal Surg* 18: 215-223.
2. Choti MA, Sitzmann JV, Tiburi MF, Sumetchotimetha W, Rangsin R, et al. (2002) Trends in long term survival following liver resection for hepatic colorectal metastases. *Ann Surg* 235: 759-766.
3. Shoham J, Theodor E, Brenner HJ, Goldman B, Lusky A, et al. (1980) Enhancement of the immune system of chemotherapy-treated cancer patients by simultaneous treatment with thymic extract. *Canc Immunol Immunother* 9: 173-180.
4. Kanda S, Mochizuki Y, Miyata Y, Kanetake H, Yamamoto N (2002) Effects of Vitamin D3-Binding Protein-Derived Macrophage Activating Factor (GcMAF) on Angiogenesis. *JNCI J Natl Cancer Inst* 94: 1311-1319.
5. Wolf E, Milazzo S, Boehm K, Zwahlen M, Horneber M (2011) Thymic peptides for treatment of cancer patients (Review). *Cochrane Database Syst Rev*.
6. Uto Y, Hori H, Kubo K, Ichihashi M, Sakamoto N, et al. (2012) GcMAF: our next-generation immunotherapy. *Nature* 485: 67-70.
7. Inui T, Kuchiike D, Kubo K, Mette M, Uto Y, et al. (2013) Clinical experience of integrative cancer immunotherapy with GcMAF. *Anticancer Res* 33: 2917-2919.